

MRI-DTI Imaging Reveals Specific Neuro-degeneration Signature in Precuneus Node of Awareness Processing in Brain under Alzheimer's Disease.

Ranjitha Ruttala, Pratik Purohit, AninditaBhattacharjee, BinduKumari,Prasun K. Roy*

Neuro-Imaging Laboratory, School of Bio-Medical Engg., Indian Instt. of Technology (B.H.U.), Varanasi 221005.

Abstract

Alzheimer's disease(AD) displays progressive neurodegenerative atrophy, causing neuronal loss affecting cognitive skills and memory. As precuneus is associated with episodic memory and is the reflexive self-awareness hub node, we consider precuneus as region-of-interest(ROI) for analysing AD. The main objective is find AD-caused alteration in nerve fibres, using diffusion tensor imaging(DTI) parameters like Mean Diffusivity(MD), Fractional Anisotropy(FA), and Nerve-tract Parameters, as number, length, volume, density, and thus, analyse the effect on precuneus by AD [when compared to normal subjects(CN)]. Normals and Alzheimer's subjects (n=50 each) were scanned with Siemens 3-tesla MRI-scanner. DTI parameters were estimated by DSI-FSL procedure, with statistical analysis using t-test/ANOVA. While ageing-process occurs in both AD and CN subjects, there is no change in "macro-structural" nerve fibre characteristics (e.g. Tract Indices: Number, density, volume, length). Contrastingly, there is significant alteration in "micro-structural" fibre characteristics, as increase in Mean Diffusivity($p=0.0006$) and decrease in Fractional Anisotropy($p=0.0009$) in Alzheimer's disease, when compared with normal subjects. Furthermore, comparing left-versus-right brain, Alzheimer's patients (but not Normal subjects) show diminution in macro-structural nerve characteristics in left precuneus (compared to right precuneus): namely Tract's number($p=0.0010$), length($p=0.0107$), volume($p=0.0225$), density($p=0.0340$). Under neurodegeneration, change in "micro-structural" nerve-fibre characteristics (Tract Indices), as opposed to "macro structural" fibre indices, can be hallmark for AD. Moreover, right precuneus is more protected in AD. Conversely, left precuneus has more neurodegeneration since its blood-flow is supplied by left common-carotid artery (unlike right common-carotid artery), this left artery arises directly from high-pressure aortic flow, transmitting turbulent hemodynamic stress to left precuneus.

Keywords: Neurodegeneration , Alzheimer's, MRI-DTI Imaging

*Corresponding author email: pkroy.bme@iitbhu.ac.in

Introduction

Neurodegeneration is a progressive disorder that damages the functionality of the neurons and ultimately leads to neuronal death with different problems like depression and hallucinations[1, 2][3]. In recent years, many neurodegenerative diseases emerged, but Alzheimer's disease (AD), a major form of Dementia, is common and affects most people through ageing[4]. According to World Health Organization, 55 million in the world population live with Dementia; among them, 60-70% cases are of AD[5].

AD is the progressive Neurodegeneration atrophy and leading disease that causes functional loss of neurons by affecting cognitive skills and memory[6]. This type of disease mainly arises along with ageing[7]. The main engender for AD is the neurofibrillary tangles and the clusters of deteriorating nerve endings due to accumulation of amyloid-beta that forms plaques between neurons[8]. Unfortunately, there is no effective therapeutics to cure to prevent AD despite the available treatments controlling symptoms and delaying disease progression[9].

For this study, we considered the region of interest as the precuneus which is more susceptible to AD as it is more vulnerable to the early accumulation of amyloid beta-protein, which acts as the pathological hallmark for AD[10, 11]. Furthermore, precuneus is the reflexive self-awareness hub node whose primary functioning is episodic memory, consciousness, and visual-spatial processing. It is a part of the superior parietal lobe in both the brain's hemispheres and surrounded by the marginal branch of the cingulate sulcus, parietooccipital sulcus, and subparietal sulcus in front, rear, and beneath the precuneus, respectively when viewed from the sagittal plane[12]. Precuneus is a part of Default Mode Network, which has unique significance in memory retention, emotion processing tasks performed through fMRI and is responsible for maximum structural and functional connectivity. Moreover, it shows high activation when the brain is at a resting state, which shows precuneus as a functional core of brain[13-15]. Our research used Diffusion Tensor Imaging (DTI) to detect microstructural white matter (WM) changes because the plaques mainly occurred on axons. Hence by quantifying the WM changes in the precuneus, the early diagnosis of AD might be possible[16].

DTI is a technique used to find the movement of water molecules inside the white matter (WM). This modality mainly follows the Brownian motion of water molecules, which shows the significance of anisotropy; considering the neuron, water can diffuse cell body in all the directions called isotropic, but in axons, the degree of movement is allowed along the axial direction and restricted to other directions called anisotropy[17]. To find the direction and degree of anisotropy, we used the white matter parameters: Fractional Anisotropy (FA), mean diffusivity (MD), Λ_1 , Λ_2 , Λ_3 . Here λ_1 , λ_2 , λ_3 are the eigenvalues that give the 3D representation of the degree of anisotropy which is specific at the neuron level. Additionally, to find the disease condition of the precuneus region, we calculated tract parameters: the number of tracts, mean tract length, density, and volume. By analysing the difference in these parameters, we can estimate to what extent the subject is healthy.

FA is associated with the fractional degree of freedom associated with the movement of water molecules within WM. Higher the FA signifies the faster movement of molecules, showing the high amount of myelination, and a decrease in FA signifies the loss of myelin due to injury or damage of neurons. MD is the average molecule's motion in three principal directions and is complementary to FA. An increase in MD shows that the molecule has the freedom to move in all directions, which reveals the injury of neurons. Several reports suggest that FA should be more for a healthy neuron, with less MD[18-20]. λ_1 represents the axon's longitudinal direction diffusion, called as Axial Diffusivity (A_xD). λ_2 , λ_3 represent the two types of radial direction of diffusion perpendicular to each other, where λ_2 is considered as lamellar diffusivity and λ_3 focal diffusivity[21].

Hence, our research aims to a detailed study of the degree and direction of diffusion and the stage of the subject condition (either healthy or disease) by calculating WM parameters and tract parameters of the precuneus region, which are essential in finding the spread of AD.

Materials and Methods

For this research study, the images for the subjects were collected from Alzheimer's disease neuroimaging initiative (ADNI-<https://adni.loni.usc.edu/>) database. It is a longitudinal multicentre study

founded by Dr. Michael W. Weiner initiated in 2004 as a private-public partnership with the main objective is to diagnose AD at the early stages and assist novel diagnostic procedures for the treatment of AD at early stages[22].

Image Acquisition

This research incorporates DTI images of 100 subjects from the ADNI, which contains cognitively normal and AD (n=50 each) from 50 to 100 years. The images were acquired with 3T scanner named Siemens(Skyra, Prisma_fit, Verio), GE Medical Systems (DISCOVERY MR750, Signa HDxt) and Philips Medical Systems (Achieva dStream, Ingenia). The acquisition parameters were as follows: Flip angle = 90 degree, gradient directions = 54, gradient values (b) = 0 s/mm² and 1000 s/mm², slice thickness = 2mm, Echo time = 82ms, repetition time = 9600ms, pulse sequence = Echo planner, matrix size = 1044 pixel x 1044 pixel x 55 pixel and the pixel size= 2mmx2mm.

Diffusion tractography

The FMRIB software library (FSL) is used to perform tractography for calculating FA, MD, A_xD, λ_2 , and λ_3 . The processing steps include (i) Brain extraction. (ii) Registering the subject space into MNI152 standard space using FMRIB's Non-Linear Image Registration Tool (FNIRT). (iii) Creating a binary mask of precuneus with a threshold of 15. (iv) Post processing is performed using DTIFIT. It will generate corresponding FA, A_xD, λ_2 , and λ_3 maps, through which we extracted the corresponding values. MD is the average of λ_1 , λ_2 , λ_3 , and axial diffusivity is λ_1 .

We used MRICron (<https://www.nitrc.org/projects/mricron>) to convert all the 3D DICOM images into 4D Nifti format by generating gradient values(bvals) and gradient vectors(bvecs) files along with JSON files (which contain acquisition details). The generated 4D image is reconstructed using DSI Studio(<https://dsistudio.labsolver.org/>) by generalized q sampling. It is a model-free or non-parametric method that does not assume any distribution, but the inference for this method is given by empirical distribution. With diffusion, the sampling length ratio of 1.25, and the number of threads is 6. For the tract generation, the precuneus is taken as the region of interest from the FreesurferDKT_cortical atlas with a QA thresholding of 0.0455, and the tracking algorithm is streamline (Euler approach). Additionally, other parameters like Angular threshold of 80, step size of 0.5, and limit the minimum and maximum length of tracts is 10mm and 400mm, respectively, need to be considered to avoid spurious and false tracts. The seed of 10⁶ is taken for the tractography[23].

Statistical Analysis

Our study utilized an unpaired t-test (parametric) to find WM parameters, tract parameters, and left vs. right hemisphere changes of precuneus between CN and AD subjects and Two-way ANOVA, followed by Tukey's post hoc test to find the age wise trajectory of WM and tract parameters of precuneus for CN and AD subjects. We used Prism-GraphPad open source platform to perform all statistical analyses, and it gives a significant difference if $p < 0.05$.

Results

In our study, we compared WM parameters, tract parameters, and left vs. right hemisphere changes in the precuneus region. Furthermore, we have made an age wise comparison of all the parameters of CN and AD.

Comparison between CN and AD in precuneus.

We compared FA, MD, A_xD, λ_2 , and λ_3 of precuneus with CN and AD. There is a decrease in FA ($p=0.0006$)(Figure 1.1), the number of tracts ($p=0.0215$)(Figure 1.2), and an increase in MD ($p=0.0009$)(Figure 1.4), A_xD ($p=0.0035$)(Figure 1.3), λ_2 ($p=0.004$)(Figure 1.5), λ_3 ($p=0.002$)(Figure 1.6) in Alzheimer's compared with normal subjects. Furthermore, we compared various tract indices like the number of tracts, mean tract length, density, and volume of the precuneus, and there is no considerable change in Alzheimer's.

Figure 1.1

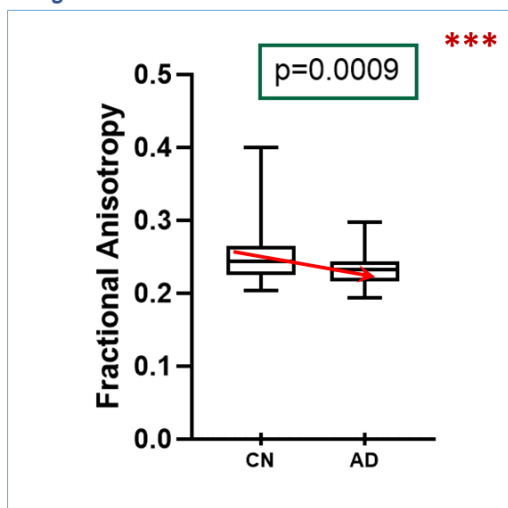


Figure 1.2

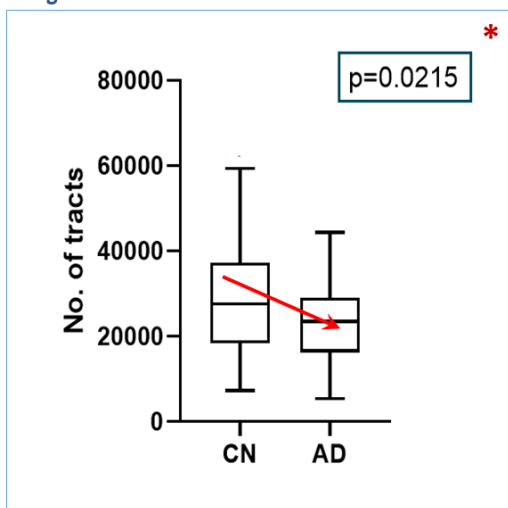


Figure 1.3

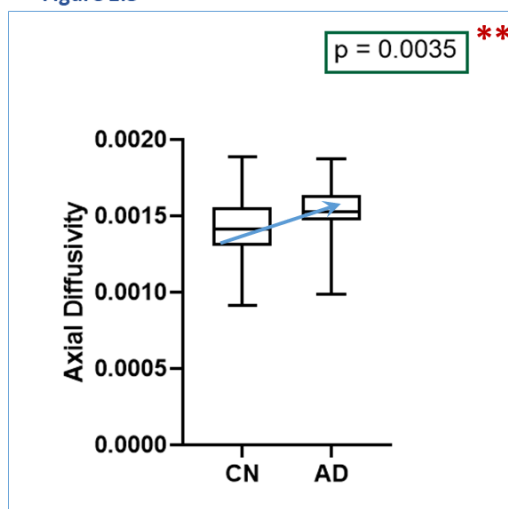


Figure 1.4

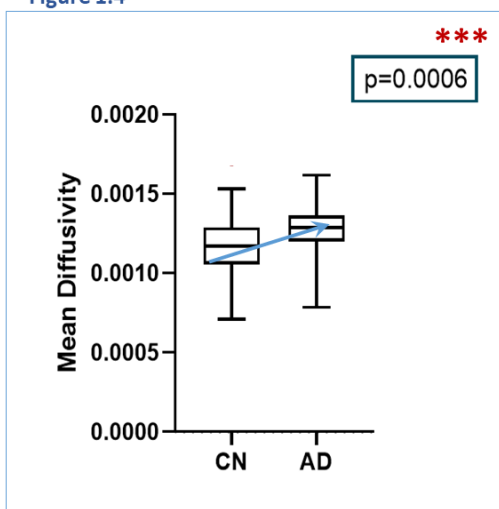


Figure 1.5

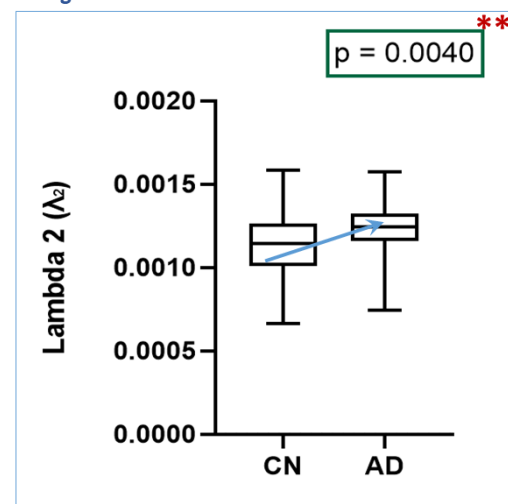


Figure 1.6

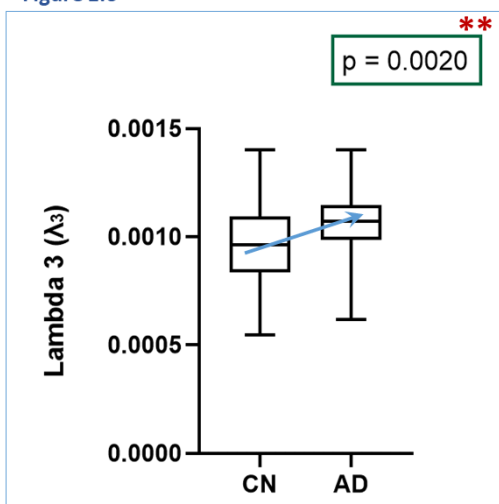


Figure 1. The comparison in Fractional Anisotropy (Figure 1.1), number of tracts (Figure 1.2), Axial diffusivity (Figure 1.3), Mean diffusivity (Figure 1.4), Lambda2(λ_2) (Figure 1.5), Lambda3(λ_3) (Figure 1.6) of precuneus between Cognitively normal(CN) and Alzheimer's disease(AD) subjects using unpaired t test. * represents significance difference between groups with $p < 0.05$, ** represents significance difference between groups with $p < 0.005$, *** represents significance difference between groups with $p < 0.001$.

Age wise comparison of CN and AD in the precuneus

In the age wise comparison of CN and AD in the precuneus, the changes observed in CN for all the parameters were as follows: For FA (Figure 2.1), there is a notable decline in the age group 90-100 when compared with 50-60 ($p=0.0178$), 60-70 ($p=0.0247$), 70-80 ($p=0.0154$), and considering the age group 80-90, it has decreased significantly compared with 50-60 ($p=0.0193$), 60-70 ($p=0.0267$), 70-80 ($p=0.0167$). For MD (Figure 2.2), with the age group 50-60, there is a significant shoot up in 70-80 ($p=0.0135$) and 90-100 ($p=0.0008$). For λ_2 (Figure 2.3), there is an increment from the age group 50-60 to 70-80 ($p=0.0443$), 90-100 ($p=0.0054$). For λ_3 (Figure 2.4), there is an increment from the age group 50-60 to 90-100 ($p=0.0042$) in CN. For A_xD (Figure 2.5), there is an increase from the age group 50-60 to 70-80 ($p=0.0245$), 90-100 ($p=0.0087$) in CN subjects.

However, there were no substantial changes in FA, MD, A_xD , λ_2 , λ_3 . Other tract indices do not have considerable changes in CN and AD subjects with aging.

Figure 2.1

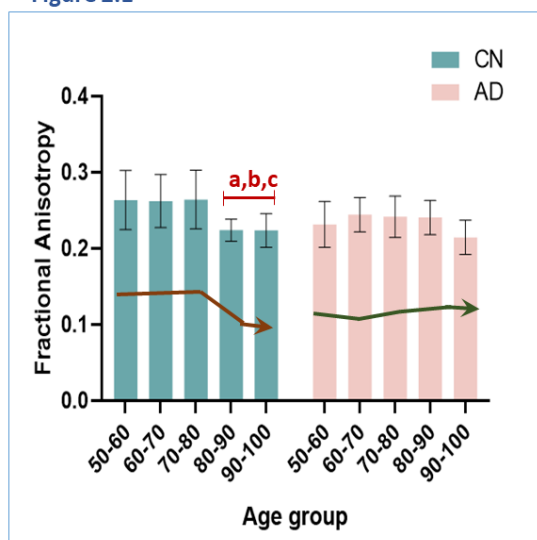


Figure 2.2

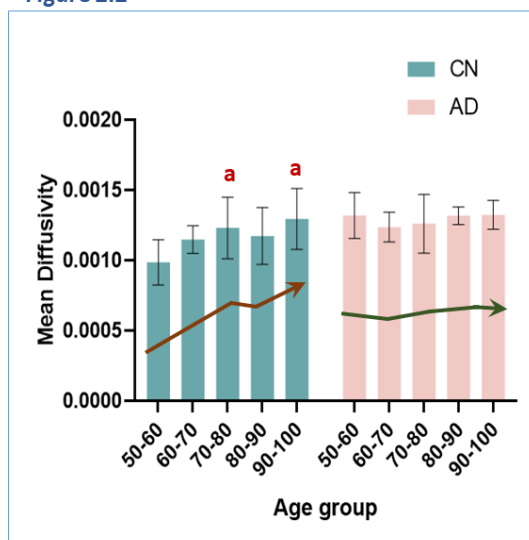


Figure 2.3

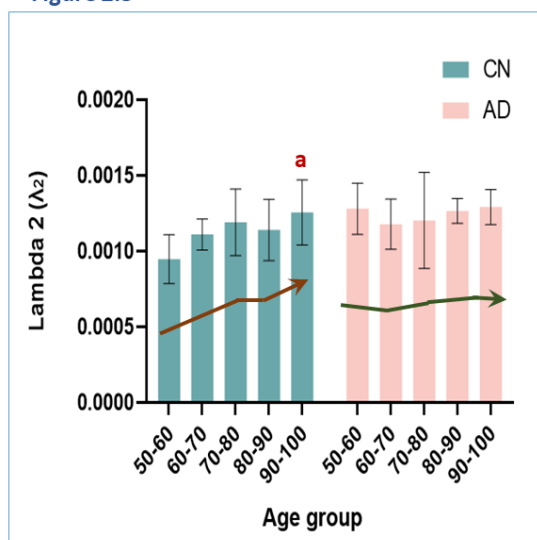


Figure 2.4

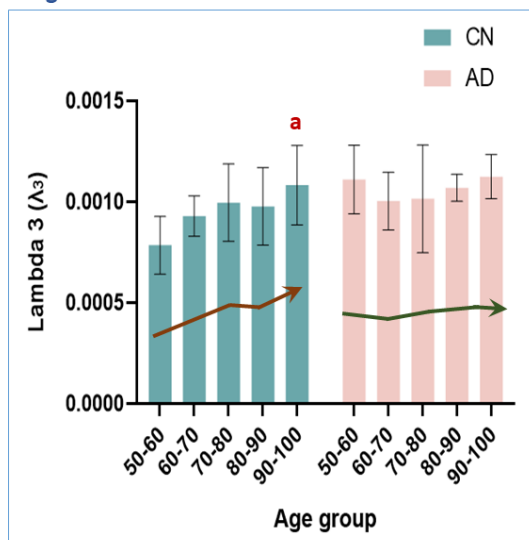


Figure 2.5

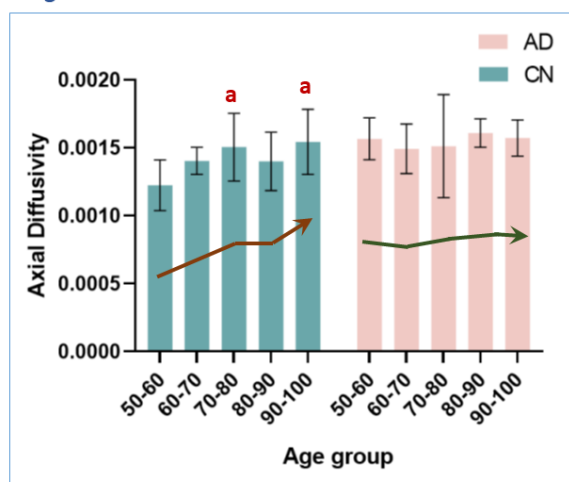


Figure 2. Agewise comparison in Fractional Anisotropy (Figure 2.1), Mean Diffusivity (Figure 2.2), λ_2 (Figure 2.3), λ_3 (Figure 2.4), Axial Diffusivity (Figure 2.5), in precuneus between Cognitively normal(CN) and Alzheimer's disease(AD) subjects. a $p < 0.05$, b $p < 0.05$, c $p < 0.05$ compared to corresponding age group with middle age group (50-60), middle-age group (60-70), old age group (70-80) with respectively using Two way Anova test.

Comparison of the left precuneus and right precuneus in CN vs. AD

We compared tract number($p=0.0010$)(Figure 3.1), mean tract length($p=0.0107$)(Figure 3.2), volume($p=0.0225$)(Figure 3.3), and density($p=0.0340$)(Figure 3.4) of left precuneus of CN to AD, there is a sharp decline in the left side of precuneus from CN to AD. Contrastingly, we compared all the respective parameters for the right side of the precuneus, and there is no significant difference between CN and AD. From the analysis, we concluded that the right side of the brain is more protected during the early onset of Alzheimer's disease.

Figure 3.1

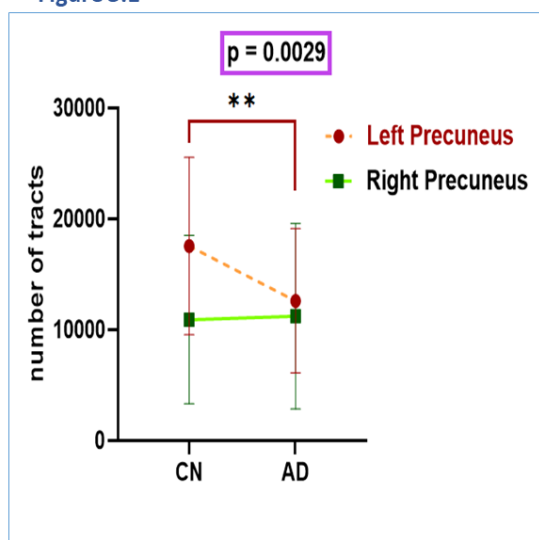


Figure 3.2

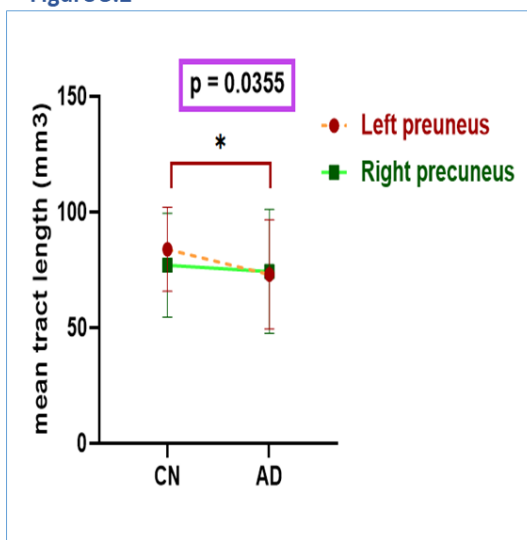


Figure 3.3

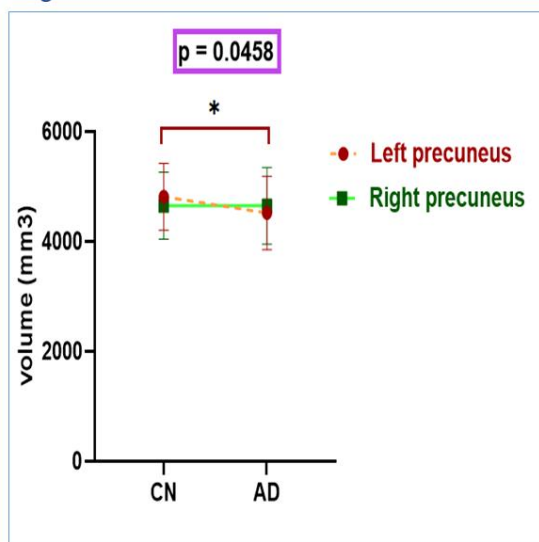


Figure 3.4

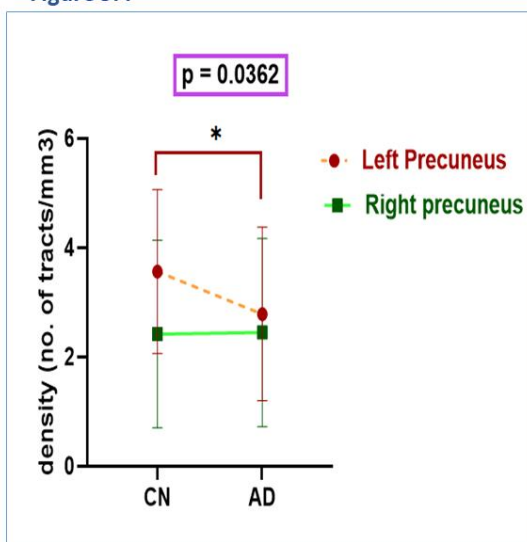


Figure 3. Comparison of the number of tracts (Figure3.1), mean tract length (Figure3.2), volume (Figure3.3), density (Figure3.4) between left precuneus vs right precuneus concerning cognitively normal (CN) and Alzheimer's disease (AD) subjects. * represents a significance difference between groups with $p < 0.05$, ** represents significant difference between groups with $p < 0.005$.

Discussion

In this present study, we have assessed the changes in WM parameters, tract parameters with (i) disease condition in the precuneus, (ii) age wise trajectory of CN and AD in the precuneus (iii) left and right precuneus. Here we represent the age groups 50-70 as the middle age group, 70-80 as the old age group, and 80-100 as the older age group. From our study, we summarise the results as follows:

Changes in WM and tract parameters with disease condition in precuneus

Our results revealed a significant decrease in FA and the number of tracts, whereas there was a considerable increase in MD. There might be a loss of myelination, so the diffusion is unrestricted to move in any direction, which eventually causes the death of neurons, thereby reducing the number of tracts [26]. Furthermore, multiple studies divulged that the role of apolipoprotein also shows the integrity of WM in memory decline[24]. Under Neurodegeneration, decreased FA, number of tracts, and increased MD sets a hallmark of Alzheimer's disease[25-27]. we observed that from CN to AD in the precuneus, there is an increase in the lamellar diffusivity(λ_2), which is the second-largest eigenvalue with significant diffusivity in the dorsoventral direction, and an increase in Focal diffusivity(λ_3) which is the least eigenvalue which has little significance in AD compared with CN; it might be associated with loss of myelin functionality [21].

Age wise effect on CN and AD in precuneus

Our current study found that FA is correlated negatively, and MD, A_xD , λ_2 , and λ_3 are correlated positively with aging in the precuneus of CN.

FA does not have any significance from middle age to old age; however, there is a considerable change from middle age to older age, which is evident that there might be notable variation in WM tracts due to tract anatomical variability[28]. Furthermore, FA stays constant from middle age to old age and then starts declining from old age to older age; this declination may be due to the consequences of the pile of water in balloons in myelin sheets which is abnormal[29, 30]. Moreover, from old age to older age, the demyelination and deprivation of axons will start from old age[31]. On the other hand, the FA parameter acts as a potential marker and helps differentiate AD from CN subjects[32].

Our findings suggest that, along with ageing in CN subjects, MD does not have significance in the middle age group. However, there is a noticeable change from middle age to old age group and older age group. Increase in MD corresponds to lessened neural tissues and their function[33]

Interestingly, our extended findings reveal an increase in A_xD , λ_2 , and λ_3 with ageing in Normals. From prior researchers' introspections of histological microscopy cellular findings of histological microscopy

Organized by Pharmacy (AY.) Course, Faculty of Ayurveda, Institute of Medical Sciences & Medical Laboratory Technology Course, Ddu, Kaushal Kendra, Rajiv Gandhi South Campus, Barkachha, Mirzapur Banaras Hindu University

cellular findings, the structure of the brain's fibres is the 3D geometrical structure formed by the arrangement of 2D planar sheet lamella. This lamella is formed by crossing the fibres, and the most significant diffusion is A_xD , the second largest is λ_2 , and the nominal diffusion value is λ_3 . Hence, an increase in A_xD may be due to Wallerian degeneration, a crucial cause of the loss of axonal functioning[34]. Furthermore, the progression of λ_2 might be demyelination because, even with minor differences in myelin and age, there will be a significant decline in λ_2 as the axon diameter and density are likely to impact[35]. The significance in λ_3 is only from middle age to older age. It corresponds to thermodynamic water diffusion or molecular mobility penetrating the neuronal myelin along the third direction and does not correspond to any fibre system of the sheet (*ibidem*) [21].

In AD, the damage has already happened to the maximum extent, so there might not be any chance to decrease further, referred to as the floor effect in the brain. Hence there is no significance in AD with aging.

Effect of AD in left and right precuneus

From our results, while comparing the tractography parameters: number of tracts, mean tract length, volume, and density of left and right precuneus with AD and CN, there is no difference in these parameters in the right precuneus from CN to AD, whereas there is a sharp decline in the left precuneus from CN to AD for all the tractography parameters which signifies that right precuneus is more protected at the early onset of AD, whereas left precuneus is more vulnerable and affected at an early stage[36]. Earlier studies suggest that uneven cerebral glucose uptake decline is more dominant in the left precuneus[37].

One of the cause of AD is because of the neurofibrillary tangles and these tangles might occur due to the neuronal inactivity[38]. Therefore, Exercising the brain might increase neuronal activity by increasing the blood flow in the brain, through which we can prevent AD to a certain extent by increasing cognitive reserve[39, 40]. Our hypothesis for our finding is that, by the comparison of the right and left precuneus functionality, there is an asymmetric relationship between both sides of the precuneus and have a distinct role for both of them[41]. The right brain is more associated with the visual cortex, and the left is responsible for learning and communication skills[42]. In the process of ageing, there might be fewer chances for the people to think, learn and speak which is associated with the left hemisphere, but there are high chances for the people to look at their surroundings as part of daily routine, which indirectly exercises the visual cortex that is associated the right side of the brain.

Besides that, the left precuneus has more neurodegeneration since its blood flow is supplied by left common carotid artery (unlike the right common carotid artery), this left artery arises directly from high-pressure aortic flow, transmitting turbulent hemodynamic stress to the left precuneus[43].

Our study concludes that an increase in FA and decrease in MD, A_xD , λ_2 , λ_3 from CN vs. AD is because of the demyelination in axons and death of neurons which further impacted the track count. Age wise comparison in CN vs. AD throws light on the normal ageing process. FA signifies the variable changes in WM indices due to tract anatomical variability. It might also signify the accumulation of water in a pile of balloons in myelin sheets which causes neurodegeneration in the older age group. It is worth mentioning that the increase in A_xD , λ_2 , λ_3 along with ageing is due to the Wallerian degeneration is associated with A_xD ; minor changes in myelin and aging might affect the axon diameter, which in turn increases λ_2 , and an increase in λ_3 corresponds to thermodynamic water diffusion that penetrating in neuron myelin in the third direction. Our culmination findings are that the right precuneus is more protected than the left in the early stages of AD. If the right side of the brain is also affected, the progression of AD can be estimated.

References

- [1]. Castillo, X., et al., Re-thinking the etiological framework of neurodegeneration. *Frontiers in Neuroscience*, 2019. 13: p. 728.
- [2]. Slanzi, A., et al., In vitro models of neurodegenerative diseases. *Frontiers in cell and developmental biology*, 2020. 8: p. 328.
- [3]. <https://www.nhs.uk/conditions/alzheimers-disease/>

- [4]. Hou, Y., et al., Ageing as a risk factor for neurodegenerative disease. *Nature Reviews Neurology*, 2019. 15(10): p. 565-581.
- [5]. <https://www.who.int/news-room/fact-sheets/detail/dementia>
- [6]. Rampa, A., et al., Emerging targets in neurodegeneration: new opportunities for Alzheimer's disease treatment? *Current Topics in Medicinal Chemistry*, 2013. 13(15): p. 1879-1904.
- [7]. Przedborski, S., M. Vila, and V. Jackson-Lewis, Series Introduction: Neurodegeneration: What is it and where are we? *The Journal of clinical investigation*, 2003. 111(1): p. 3-10.
- [8]. Sun, X., W.-D. Chen, and Y.-D. Wang, β -Amyloid: the key peptide in the pathogenesis of Alzheimer's disease. *Frontiers in pharmacology*, 2015. 6: p. 221.
- [9]. Hrelia, P., et al., Common protective strategies in neurodegenerative disease: focusing on risk factors to target the cellular redox system. *Oxidative Medicine and Cellular Longevity*, 2020. 2020.
- [10]. Sperling, R.A., et al., Amyloid deposition is associated with impaired default network function in older persons without dementia. *Neuron*, 2009. 63(2): p. 178-188.
- [11]. Herrera-Rivero, M., Late-onset Alzheimer's disease: risk factors, clinical diagnosis and the search for biomarkers. *Neurodegenerative Diseases*, 2013.
- [12]. <https://en.wikipedia.org/wiki/Precuneus>
- [13]. Rami, L., et al., Distinct functional activity of the precuneus and posterior cingulate cortex during encoding in the preclinical stage of Alzheimer's disease. *Journal of Alzheimer's disease*, 2012. 31(3): p. 517-526.
- [14]. Yokoi, T., et al., Involvement of the precuneus/posterior cingulate cortex is significant for the development of Alzheimer's disease: a PET (THK5351, PiB) and resting fMRI study. *Frontiers in Aging Neuroscience*, 2018: p. 304.
- [15]. Li, R., et al., Developmental maturation of the precuneus as a functional core of the default mode network. *Journal of cognitive neuroscience*, 2019. 31(10): p. 1506-1519.
- [16]. Esrael, S.M.A.M., et al., Application of diffusion tensor imaging in Alzheimer's disease: quantification of white matter microstructural changes. *Egyptian Journal of Radiology and Nuclear Medicine*, 2021. 52(1): p. 1-8.
- [17]. <https://radiopaedia.org/articles/diffusion-tensor-imaging-and-fibre-tractography>
- [18]. Bergamino, M., R.R. Walsh, and A.M. Stokes, Free-water diffusion tensor imaging improves the accuracy and sensitivity of white matter analysis in Alzheimer's disease. *Scientific reports*, 2021. 11(1): p. 1-12.
- [19]. Nir, T.M., et al., Effectiveness of regional DTI measures in distinguishing Alzheimer's disease, MCI, and normal aging. *NeuroImage: clinical*, 2013. 3: p. 180-195.
- [20]. Mayo, C.D., et al., Relationship between DTI metrics and cognitive function in Alzheimer's disease. *Frontiers in aging neuroscience*, 2019: p. 436.
- [21]. Pareek, V., et al., Patterning of corpus callosum integrity in glioma observed by MRI: Effect of 2D bi-axial lamellar brain architecture. *Journal of Neuro-Oncology*, 2019. 144(1): p. 165-177.
- [22]. <https://adni.loni.usc.edu/about/>
- [23]. Silva, P.H.R.d., et al., Brain Structural-Functional Connectivity Relationship Underlying the Information Processing Speed. *Brain Connectivity*, 2020. 10(3): p. 143-154.
- [24]. Lee, Y.M., et al., Impact of Apolipoprotein E4 Polymorphism on the Gray Matter Volume and the White Matter Integrity in Subjective Memory Impairment without White Matter Hyperintensities: Voxel-Based Morphometry and Tract-Based Spatial Statistics Study under 3-Tesla MRI. *Journal of Neuroimaging*, 2016. 26(1): p. 144-149.
- [25]. Stebbins, G. and C. Murphy, Diffusion tensor imaging in Alzheimer's disease and mild cognitive impairment. *Behavioural neurology*, 2009. 21(1-2): p. 39-49.
- [26]. Mayo, C.D., et al., Longitudinal changes in microstructural white matter metrics in Alzheimer's disease. *NeuroImage: Clinical*, 2017. 13: p. 330-338.
- [27]. Grieve, S.M., et al., Cognitive aging, executive function, and fractional anisotropy: a diffusion tensor MR imaging study. *American Journal of Neuroradiology*, 2007. 28(2): p. 226-235.

- [28]. Matijevic, S. and L. Ryan, Tract Specificity of Age Effects on Diffusion Tensor Imaging Measures of White Matter Health. *Frontiers in Aging Neuroscience*, 2021. 13: p. 94.
- [29]. Feldman, M.L. and A. Peters, Ballooning of myelin sheaths in normally aged macaques. *Journal of neurocytology*, 1998. 27(8): p. 605-614.
- [30]. Westlye, L.T., et al., Life-span changes of the human brain white matter: diffusion tensor imaging (DTI) and volumetry. *Cerebral cortex*, 2010. 20(9): p. 2055-2068.
- [31]. Xie, S., et al., Subcortical white matter changes with normal aging detected by multi-shot high resolution diffusion tensor imaging. *Plos one*, 2016. 11(6): p. e0157533.
- [32]. Qiu, A., et al., Surface-based analysis on shape and fractional anisotropy of white matter tracts in Alzheimer's disease. *PloS one*, 2010. 5(3): p. e9811.
- [33]. Takeuchi, H., et al., Empathizing associates with mean diffusivity. *Scientific reports*, 2019. 9(1): p. 1-13.
- [34]. B. Parente, D., et al., Potential role of diffusion tensor MRI in the differential diagnosis of mild cognitive impairment and Alzheimer's disease. *American Journal of Roentgenology*, 2008. 190(5): p. 1369-1374.
- [35]. Rathee, R., V.S. Rallabandi, and P.K. Roy, Age-related differences in white matter integrity in healthy human brain: evidence from structural MRI and diffusion tensor imaging. *Magnetic resonance insights*, 2016. 9: p. MRI. S39666.
- [36]. Loewenstein, D.A., et al., Predominant left hemisphere metabolic dysfunction in dementia. *Archives of Neurology*, 1989. 46(2): p. 146-152.
- [37]. Weise, C.M., et al., Left lateralized cerebral glucose metabolism declines in amyloid- β positive persons with mild cognitive impairment. *NeuroImage: Clinical*, 2018. 20: p. 286-296.
- [38]. Hatanpää, K., et al., Neuronal activity and early neurofibrillary tangles in Alzheimer's disease. *Annals of Neurology: Official Journal of the American Neurological Association and the Child Neurology Society*, 1996. 40(3): p. 411-420.
- [39]. Chirles, T.J., et al., Exercise training and functional connectivity changes in mild cognitive impairment and healthy elders. *Journal of Alzheimer's disease*, 2017. 57(3): p. 845-856.
- [40]. Brosnan, M.B., et al., Plasticity of the right-lateralized cognitive reserve network in ageing. *Cerebral Cortex*, 2018. 28(5): p. 1749-1759.
- [41]. Petrini, K., et al., Look at those two!: The precuneus role in unattended third-person perspective of social interactions. *Human Brain Mapping*, 2014. 35(10): p. 5190-5203.
- [42]. Cavanna, A.E. and M.R. Trimble, The precuneus: a review of its functional anatomy and behavioural correlates. *Brain*, 2006. 129(3): p. 564-583.
- [43]. Roy, P.K., MRI-Analysis of Neurodevelopmental Inversion of Allocortex for Fast Screening of Seizure Patients: A Clinical Informatics Approach.